

Glaucoma glossary

Written by Administrator

Wednesday, 13 January 2010 11:27 - Last Updated Thursday, 21 January 2010 23:34

angle closure glaucoma

A type of glaucoma caused by a sudden and severe rise in eye pressure. Occurs when the pupil enlarges too much or too quickly, and the outer edge of the iris blocks the eye's drainage canals. Can be either acute or chronic.

aqueous humour

The fluid produced in the front part of the eye.

bleb

An slightly raised area under the eyelid, on the surface of the eye itself, that lies over the new drainage opening created during surgery.

central vision

What is seen when you look straight ahead or when you read.

ciliary body

Tissues located around the lens of the eye that supply fluid to nourish the eye.

congenital glaucoma

A rare form of glaucoma that occurs in babies and young children. This condition can be inherited. It is usually the result of incorrect or incomplete development of the eye's drainage canals during the prenatal period.

conjunctiva

A thin, clear membrane that lines the inner surface of the eyelids and the outer surface of the eyeball, except for the cornea.

Glaucoma glossary

Written by Administrator

Wednesday, 13 January 2010 11:27 - Last Updated Thursday, 21 January 2010 23:34

cornea

The clear part of the eye located in front of the iris.

drainage canals

Small openings around the outer edge of the iris. These canals provide the final pathway for fluid to leave the inside of the eye. Also referred to as the trabecular meshwork or Schlemm's canal.

glaucoma suspect

A person may be considered a glaucoma suspect on the basis of high intraocular pressure, an unusual appearance of the optic disc or visual field, a family history of glaucoma, or narrow angles between the iris and cornea.

gonioscopy

In this test, a contact lens that contains a mirror is gently placed on the eye. The mirror lets the doctor look sideways into the eye to check whether the angle where the iris meets the cornea is open or closed. This helps the doctor decide whether open angle or angle closure glaucoma is present.

intraocular pressure (IOP)

The inner pressure of the eye. Normal intraocular pressure usually ranges from 12-22 mm Hg, although people with relatively low pressures can still have glaucoma (see normal tension glaucoma).

iris

The colored part of the eye that can expand or contract to allow the right amount of light to enter the eye.

laser surgery

A type of surgery in which a tiny, powerful beam of energy is used to solve problems in the eye. There are three common forms of laser surgery for glaucoma:

Glaucoma glossary

Written by Administrator

Wednesday, 13 January 2010 11:27 - Last Updated Thursday, 21 January 2010 23:34

laser peripheral iridotomy: creates a new drainage hole in the iris, allowing the iris to fall away from the outflow channel so fluid can drain out of the eye.

laser trabeculoplasty: in this procedure, the laser is aimed toward the normal drainage channels of the eye, in an attempt to open those channels so fluid can leave the eye more efficiently.

laser cyclophotocoagulation: this laser procedure is usually used in people who have severe glaucoma and are not responding to standard glaucoma surgery. The laser is used to partially destroy the tissues that make the fluid in the eye.

lens

Located behind the iris, the lens directs light onto the retina.

microsurgery

Surgery performed with a microscope in which a tool is used to make a tiny, new opening in the sclera so that intraocular fluid can drain out of the inside of the eye.

mm Hg

An abbreviation for millimetres of mercury, a scale for recording intraocular pressure.

normal tension glaucoma

Also called low tension glaucoma. A rare form of glaucoma in which intraocular pressure stays within the normal range (12-22 mm Hg), but damage still occurs to the optic nerve and visual fields.

ophthalmoscopy

A test used in glaucoma management to view the optic nerve. A device with a small light on the end is held up to the inside of the eye in a darkened room. This device lights up and magnifies the eye, so that the shape and colour of the optic nerve can be seen.

Glaucoma glossary

Written by Administrator

Wednesday, 13 January 2010 11:27 - Last Updated Thursday, 21 January 2010 23:34

optic nerve

The nerve in the back of the eye that carries visual images to the brain.

perimetry

Also known as the visual field test. A test that produces a map of the complete field of vision, to check whether there is damage to any area of vision.

peripheral vision

The surrounding areas of vision. These are usually the first areas of vision affected by glaucoma. Also referred to as "side vision".

primary open angle glaucoma

The most common form of glaucoma in the UK. This form of glaucoma usually develops very slowly as the eye's drainage canals gradually become clogged. There are no early warning signs for primary open angle glaucoma, which is why it is often called the "sneak thief of sight." Also known as open angle glaucoma.

pupil

The opening that monitors how much light enters the inner part of the eye.

retina

The part of the eye that transmits light and images to the brain through the optic nerve.

sclera

The tough, white, outer protective covering of the eye.

secondary open angle glaucoma

A form of glaucoma that occurs as the result of an eye injury, inflammation, or tumour. Includes pigmentary glaucoma and steroid-induced glaucoma.

Glaucoma glossary

Written by Administrator

Wednesday, 13 January 2010 11:27 - Last Updated Thursday, 21 January 2010 23:34

selective laser trabeculoplasty (SLT)

A type of laser surgery that uses a combination of frequencies allowing the laser to work at very low levels. It treats specific cells “selectively” and leaves untreated portions of the trabecular meshwork (the mesh-like drainage canals surrounding the iris) intact.

tonometry

The use of a device to measure the pressure in the eye. There are two types of tonometry:

Air Puff: This is the only type of tonometry that does not touch the surface of the eye. The patient sits facing the instrument, and a warm puff of air is directed at the eye.

Applanation: The patient’s eye is first treated with numbing drops and a stain called fluorescein. The tonometer is then placed gently on the cornea, and a very small amount of pressure is applied to the cornea. The patient may sit in front of the tonometer or a hand-held tonometer may be used.

trabecular meshwork

The mesh-like drainage canals in the drainage angle.

5-FU

A medication designed to stop the healing process. Sometimes used around the bleb to stop it from healing or scarring over.

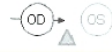Glaucoma glossary

Written by Administrator

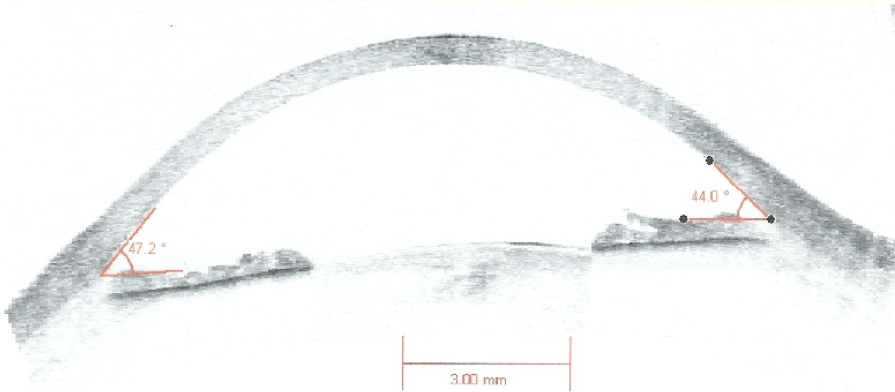
Wednesday, 13 January 2010 11:27 - Last Updated Thursday, 21 January 2010 23:34

Anterior Segment Single

178°



358°



OCT showing open angle.